

Endoscopic Management of Bilio-Pleural Fistula following Thoracoabdominal Trauma

Tejas Nimba Nikumbh^{1*}, Parth Vinod Barot², Utkrant Anant Kurlekar², Amol Mahadeo Bapaye³

ABSTRACT

Penetrating thoracoabdominal trauma, with potential injury to two anatomic cavities, poses a significant diagnostic and therapeutic challenge. This is especially true with reference to detection of diaphragmatic injuries, where development of a bilio-pleural fistula is a rare phenomenon. The optimal management in such cases has not been clearly defined as both conservative and emergency surgical approaches have been tried in acute settings. We report a patient who suffered an accidental penetrating wound to the right thoracoabdominal region. The patient developed a bilio-pleural fistula immediately following the injury with imaging showing an intact diaphragm. The case was managed conservatively using endoscopy as the primary modality for treating the primary condition as well as a rare complication of biliary stent migration. Thus an endoscopic approach is feasible in management of bilio-pleural fistula when used in properly selected cases.

Key words: Bilio-pleural fistula, Thoracoabdominal trauma, ERCP, Stent migration.

Tejas Nimba Nikumbh^{1*}, Parth Vinod Barot², Utkrant Anant Kurlekar², Amol Mahadeo Bapaye³

¹Department of General Surgery, Grant Medical College and Sir J.J. Group of Hospitals, Mumbai, Maharashtra, INDIA.

²Department of General Surgery, Deenanath Mangeshkar Hospital and Research Centre, Pune, Maharashtra, INDIA.

³Department of Gastroenterology, Deenanath Mangeshkar Hospital and Research Centre, Pune, Maharashtra, INDIA.

Correspondence

Dr. Tejas Nimba Nikumbh

A-1, Suryadarshan CHS, Arunodaya Nagar, Mulund-East, Mumbai – 400081, Maharashtra, INDIA.

Phone: +91 80077 32893

Email: drtejasnikumbh@gmail.com

History

- Submission Date: 13-08-2017;
- Review completed: 07-09-2017;
- Accepted Date: 22-09-2017;

DOI : 10.5530/ogh.2018.7.1.14

Article Available online

<http://www.oghreports.org>

Copyright

© 2018 Phcog.Net. This is an open-access article distributed under the terms of the Creative Commons Attribution 4.0 International license.

INTRODUCTION

Bilio-Pleural Fistula (BPF) following penetrating thoracoabdominal trauma is a rare and atypical presentation. The potential to injure two anatomic cavities, significantly challenges surgical management, especially with reference to detection of diaphragmatic injuries. The optimal management of hemodynamically stable, asymptomatic patients with thoraco-abdominal penetrating wounds remains controversial. Isolated diaphragmatic injury in asymptomatic patients cannot be reliably delineated by either local wound exploration, serial physical examination or peritoneal lavage. Due to their safety and cost-effectiveness, computed tomography imaging and non-operative modalities like ERCP have a definite role. We report a patient who suffered a bizarre accidental penetrating wound to the right thoracoabdominal region and was managed non-operatively.

CASE REPORT

A 52 year old Male was brought to emergency department with accidental injury to the right thoracoabdominal wall. A twig from the branch of a falling tree had penetrated through his 2nd right intercostal space (Figure 1). It measured approximately 2.5 cm in diameter and had penetrated about 10 cm deep. It was pulled out before he was brought to the emergency room. On initial examination, the patient was tachycardic, tachypnoeic with decreased breath sounds on right side of chest. A tube thoracostomy through the triangle of safety was done, following which the patient stabilized. The wound was explored to rule out any foreign body and primary closure was

done. Patient was shifted in an ICU, where he was intubated and electively put on mechanical ventilation (Figure 2). CT Chest + Abdomen revealed a grade 4 laceration to segment VIII of liver, while no obvious diaphragmatic tear was reported. Figure 3 and 4 Epidural analgesia was used to supplement pain relief. On day 3 of admission, there was bilious soakage of the chest wound, also the Intercostal drain showed bilious drain, following which a repeat CT revealed only a suspicious fluid tract in subcutaneous plane, while no obvious damage to the diaphragm could be seen. An ERCP revealed leak in the right hepatic duct for which biliary stenting was done across the rent. The patient's condition improved rapidly following this. The drain output progressively decreased and was extubated on day 5. Patient was discharged following ICD removal on day 10.

The patient was again brought to emergency department 6 weeks after the initial episode with pain in upper abdomen which did not respond to antacids and regular analgesics. A check ultrasound revealed a collection in lesser sac (70 cc). This was further evaluated with a CT scan which revealed a migrated CBD stent perforating the junction of 3rd and 4th part of duodenum. The stent was passing between the jejunal loops with its tip in the right lumbar region. Endoscopy showed the migrated stent perforating the duodenum. It was removed using a grasper and the rent was stapled endoscopically (3 in number). The patient was then kept NPO for 4 days, and gradually started on oral feeds. The patient's condition gradually improved and was discharged in a stable condition.

Cite this article: Nikumbh TN, Barot PV, Kurlekar UV, Bapaye AM. Endoscopic Management of Bilio-Pleural Fistula following Thoracoabdominal Trauma. OGH Reports. 2018;7(1):67-9.

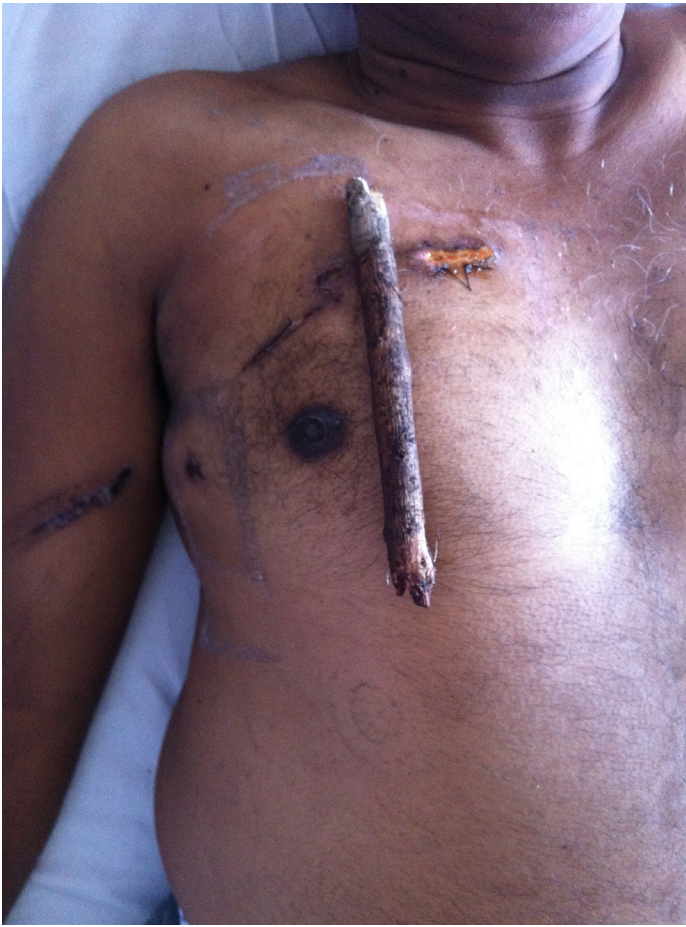

Figure 1: Twig of Falling Tree Penetrating into Thorax through 2nd Intercostal Space reaching upto Liver.

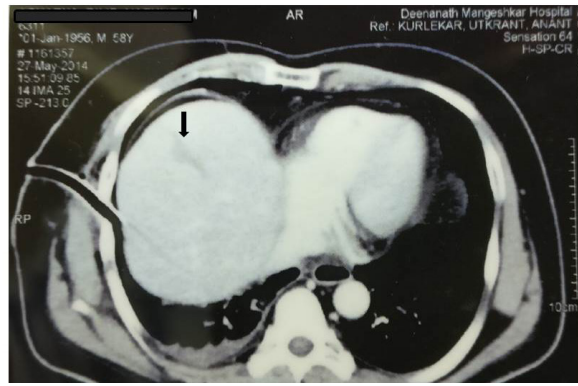


Figure 3: C.T. Chest + Abdomen with Inter Costal drain *in situ*. Black arrow: Liver Laceration.

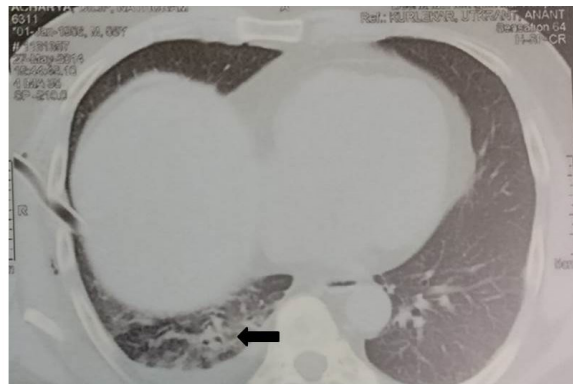

Figure 4: H.R.C.T. Chest, post ICD insertion. Diaphragm was intact. Black arrow: Lung contusion with Hemothorax.

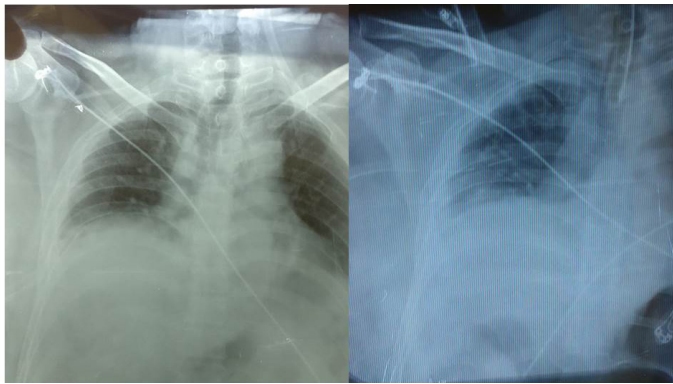


Figure 2: Chest Radiographs, a) Day 0 Post ICD insertion, b) Day 3 while patient was electively ventilated.

DISCUSSION

Bilio-pleural fistula, first described by Graham in 1897, is a rare complication of thoracoabdominal trauma. BPF has been reported in the scientific literature as a complication of inflammatory or neoplastic conditions affecting the liver, secondary to subphrenic collection, or following hepatobiliary intervention.^[1,2,3,4,5] On rare occasions, spontaneous bilio-pleural fistula does occur in patients with gall stones.^[6] Rarely bile can reach di-

rectly into the bronchial tree by means of a broncho-biliary fistula and results in bilioptysis.^[7]

Early diagnosis of BPF is crucial in the management of this condition. A delayed diagnosis leads to the development of several complications that may warrant extensive surgery. Although biliothorax does not develop immediately following trauma, as the fistulous tract usually takes an average time of 2 weeks to mature and hence it is usually missed during initial emergency surgery.^[8] In our case, the presentation was acute and was evaluated further with ERCP and CT scan. Thus, a high index of suspicion and early diagnosis of BPFs is the key for successful management. Complications associated with BPF can thus be prevented, viz. a loculated bilious empyema, which may subsequently entrap the lung and compromise lung functions. Severe cases of bronchobiliary fistula may present with necrotising bronchitis or bronchopneumonia or, rarely, chronic indirect pneumonitis.^[9]

Abdominal ultrasonography and CT scan do not delineate the presence and location of fistulas either, but they may help in detection of drainable collection. Endoscopic retrograde cholangiopancreatography (ERCP) is the imaging modality of choice for demonstrating the fistulous tract, site of bile leak and also to identify any distal obstruction, if present. ERCP also carries the therapeutic potential of sphincterotomy and biliary stenting.^[10]

The second hit in our case was when the patient presented again after 6 weeks with pain in abdomen. Intestinal perforation is a rare but serious late complication of distal migration of a biliary stent. Less than 1% of migrated stents however cause intestinal perforation. The treatment of choice is surgery.^[11] However, this was again managed using extraction

endoscopy. The case was managed actively using non operative modalities and is an established approach in BPF.^[12] the unusual manner in which a biliocutaneous fistula presented required a good clinical acumen to be detected when the CT revealed no definite diaphragmatic tear initially.

In conclusion, a high index of suspicion for anticipating rare complications following trauma as well as after endoscopic stenting. The initial management in such cases which are hemodynamically stable should be conservative and only after the non-invasive modalities have been exhausted, operative management should be contemplated.

CONFLICTS OF INTEREST

None.

ACKNOWLEDGEMENT

I would like to express my gratitude to all my teachers and colleagues at the Department of General Surgery, Deenanath Mangeshkar Hospital and Research Centre. I thank all our patients for the faith they have in us.

ABBREVIATIONS USED

ERCP: Endoscopic retrograde cholangiopancreatography; **BPF:** Bilio-Pleural Fistula; **CT:** Computed Tomography; **CBD:** Common Bile Duct; **NPO:** Nil Per Oral; **ICD:** InterCostal Drain.

REFERENCES

1. Graham SE. Observations on bronchobiliary fistula. *EMJ*. 1897;1:1397-400.
2. Strange C, Allen ML, Freedland P, *et al.* Bilipleural fistula as a complication of percutaneous biliary drainage: experimental evidence for pleural inflammation. *Am Rev Respir Dis*. 1988;137:959-61.
3. Lee MT, His SC, Hu P, *et al.* Biliopleural fistula: a rare complication of percutaneous transhepatic gallbladder drainage. *World J Gastroenterol*. 2007;13:3268-70.
4. Ghritlaharey RK. Posttraumatic bilothorax in a child: a case report. *J Clin Diagn Res*. 2008;2:760-3.
5. Lewis JR, Te HS, Gehlbach B, *et al.* A case of biliopleural fistula in a patient with hepatocellular carcinoma. *Nat Rev Gastroenterol Hepatol*. 2009;6:248-51.
6. Cunningham LW, Grobman M, Paz HL, Hanlon CA, Promisloff RA. Cholecystopleural fistula with cholelithiasis presenting as a right sided pleural effusion. *Chest*. 1990;97:751-2. [PubMed]
7. Fröbe M, Kullmann F, Schölmerich J, Böhme T, Müller-Ladner U. Bronchobiliary fistula associated with combined abscess of lung and liver. *Med Klin (Munich)*. 2004;99:391-5. [PubMed]
8. Feld R, Wechsler RJ, Bonn J. Biliary-pleural fistulas without biliary obstruction: Percutaneous catheter management. *AJR Am J Roentgenol*. 1997;169:381-3. [PubMed]
9. Johnson NM, Chin R Jr, Haponik EF. Thoracobiliary fistula. *South Med J*. 1996;89:335-9.
10. Geenen JE, Touoli J, Hogan WJ, *et al.* Endoscopic sphincterotomy: follow-up evaluation of effects on the sphincter of Oddi. *Gastroenterology*. 1984;7:54-8.
11. Issa H, Nahawi M, Bseiso B, Al-Salem A. Migration of a biliary stent causing duodenal perforation and biliary peritonitis. *World Journal of Gastrointestinal Endoscopy*. 2013;5(10):523-6.
12. Singh B, Moodley J, Sheik-Gafoor MH, *et al.* Conservative management of thoracobiliary fistula. *Ann Thorac Surg*. 2002;73:1088-91.

Cite this article: Nikumbh TN, Barot PV, Kurlekar UV, Bapaye AM. Endoscopic Management of Bilio-Pleural Fistula following Thoracoabdominal Trauma. *OGH Reports*. 2018;7(1):67-9.