

FNAC diagnosis of gallbladder adenocarcinoma presenting as multiple skin nodules and jaundice

Santosh Kumar Mondal, Debashish Bhattacharjee

ABSTRACT

Cutaneous metastasis is a rare manifestation of visceral malignancies, a phenomenon seen in 1% to 3% of all metastasizing tumors. A 62 years old female presented with multiple skin nodules in the neck and jaundice for 2 months. FNAC from the skin nodules revealed hypercellular smear composed of malignant epithelial cells arranged in clusters and glandular patterns. A provisional diagnosis of metastatic adenocarcinoma was given. USG and CT-scan of abdomen revealed a tumor in gallbladder fossa. USG guided FNAC and later on histopathological examination from the biopsy of the gallbladder tumor clinched the diagnosis of moderately differentiated gallbladder adenocarcinoma. Biopsy from the skin nodules revealed adenocarcinoma metastasis in skin. The patient was given postoperative chemotherapy and radiotherapy. Follow up period (3 months) was eventful.

Key words: Gallbladder carcinoma, Jaundice, Cutaneous metastasis, Ultrasonography, FNAC.

INTRODUCTION

Cutaneous metastasis is an uncommon manifestation of visceral malignancies.^[1] It is stated in literature that skin metastasis occurs in only 1% to 3% of all metastasizing tumors. The most common tumors to metastasize to the skin are breast, lung, colorectal, renal, and ovarian carcinomas.^[2,3] Gallbladder carcinoma commonly metastasizes to liver, regional lymph nodes however, skin metastasis is extremely rare.^[3] The rarity of the skin metastasis and its ability to mimic various primary skin tumors makes clinical diagnosis often challenging. A high index of suspicion is required on both the clinicians and pathologist's part to make a correct diagnosis. An early diagnosis of skin metastasis is crucial for detection of a previously undetected malignancy or an early sign of recurrence of a previously treated malignancy. The diagnosis of skin metastasis bears important therapeutic and prognostic values.^[4] we report a case in which gallbladder adenocarcinoma presented with cutaneous metastasis diagnosed by FNAC and histopathological examination.

CASE REPORT

A 62 year old lady presented in the dermatology outpatient department with multiple skin nodules in the right side of the neck for 1 month. She also complained of nausea, vomiting, loss of appetite, abdominal fullness for last 3 months and yellowish discoloration of urine and eye for last 2 months. [Figure 1A].

On examination, the skin nodules were hard in consistency, fixed to underlying structure; the largest measuring 1.5×1 cm. Clinically, the patient had jaundice. On abdominal examination, no organomegaly was noted except for slight liver enlargement. Examination of other systems was within normal limits. The hemogram was unremarkable except serum bilirubin was 3.7 mg/dL and serum alkaline phosphatase was 1780 IU/L. FNAC from the skin nodules showed features suggestive of metastatic adenocarcinoma. Cytological features-the malignant epithelial cells were arranged in disorganized sheets, aggregates, acini and single pleomorphic cells. [Figure 1B].

Individual cells were pleomorphic having round to oval nuclei with mild to moderate cytoplasm, increased nuclear cytoplasmic ratio, irregular nuclear outline, clumped chromatin, prominent nucleoli. [Figure 1C].

Patient was investigated for a primary neoplasm. Computed tomographies (CT) scan and X-ray of the chest was within normal limits. Ultrasound and CT scan of the whole abdomen revealed a growth in gall bladder fossa, which was infiltrating into the liver along with enlarged regional lymph nodes. [Figure 1D]. Ultrasonographic (USG)-guided FNAC smears from the gallbladder showed features of adenocarcinoma. [Figure 2E]. Biopsy was taken from the gallbladder mass and subjected to histopathological examination and a diagnosis of moderately differentiated gallbladder adenocarcinoma was given [Figure 2H]. Biopsy taken from the skin

**Santosh Kumar Mondal,
Debashish Bhattacharjee**

Department of Pathology, B.S. Medical College, Bankura, West Bengal, INDIA

Correspondence

Dr. Santosh Kumar Mondal,
"Subarnabhoomi Complex", Flat- A 302,
Block Kamini-3, 204 R N Guha Road,
Dumdum, Kolkata-700028, INDIA.

Phone no: 9433894629

Email: dr_santoshkumar@hotmail.com

History

- Submission Date: 03-05-2016;
- Review completed: 20-08-2016;
- Accepted Date: 22-09-2016.

DOI : 10.5530/ogh.2017.6.1.5

Article Available online

<http://www.oghreports.org/v6/i1>

Copyright

© 2016 Phcog.Net. This is an open-access article distributed under the terms of the Creative Commons Attribution 4.0 International license.

Cite this article: Mondal SK, Bhattacharjee D. FNAC diagnosis of gallbladder adenocarcinoma presenting as multiple skin nodules and jaundice. OGH Reports. 2017;6(1):23-5.

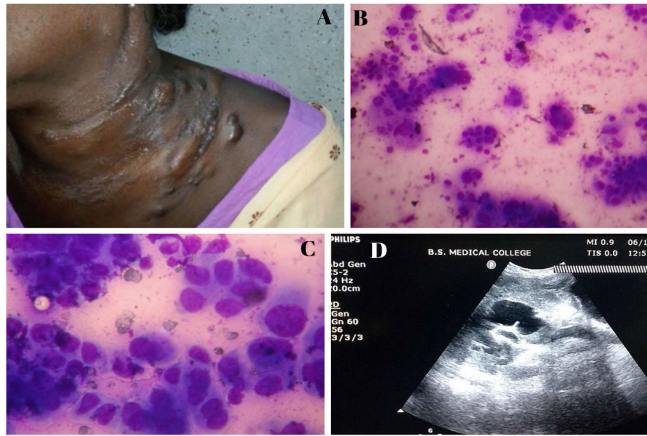


Figure 1: A : multiple skin nodules on neck of the patient, hard and fixed to underlying structure. B : FNAC from skin nodule showing malignant cells arranged in aggregates, glandular patterns and singly . (Leishman and Giemsa x 100) . C : The tumor cells are large pleomorphic having high N:C ratio , anisonucleosis and prominent nucleoli . (Leishman and Giemsa x 400) . D: USG whole abdomen showing a hypoechoic mass in gallbladder fossa with irregular margin.

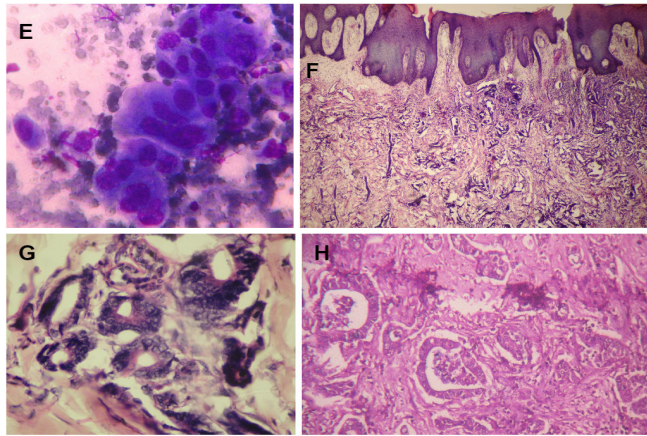


Figure 2: E : USG guided FNAC from gallbladder mass showing malignant epithelial cells arranged in aggregates and in glandular patterns (Leishman and Giemsa x 400) . F: Biopsy from skin nodules showing infiltration of malignant epithelial cells into dermis which are arranged in glandular patterns and in sheets. Epidermis is not involved. (H & E x 100) . G: High power view of skin biopsy showing malignant epithelial cells arranged in glandular patterns (H & E x 400) . H : Section from the gallbladder showing histological features of gallbladder adenocarcinoma . (H & E x 400) .

nodules, on histological examination revealed dermis infiltrated by malignant columnar cells arranged in glandular patterns and sheets, with a desmoplastic stroma. The epidermis was uninvolved. [Figure 2F. Figure 2G]. On the basis of cytomorphological, histological features, she was diagnosed as a case of adenocarcinoma gall bladder with cutaneous metastases. The patient received 3 cycles of chemotherapy for the unresectable gallbladder carcinoma consisting of 5-fluorouracil, cisplatin and calcium folinate. 3 months of follow-up was uneventful.

DISCUSSION

Cutaneous metastases are diagnostically important because they may be the first manifestation of an unknown primary malignancy, as in our case. Skin metastasis can also be a sign of dissemination of a previously diagnosed malignancy, or first sign of recurrence in a supposedly adequately treated malignancy thought to be in remission. The diagnosis of skin metastasis can determine the staging of a malignant disease and its management.^[4,5] Skin metastasis when present can be detected earlier than metastasis to other organs, therefore it becomes important for both clinicians and the pathologists to suspect and diagnose them. Rare occurrence of skin metastasis as an initial manifestation of internal malignancy, results in wide variation in clinical diagnoses. It can range from primary skin tumor to inflammatory/non-neoplastic condition.^[6] 45% of skin metastasis are even not suspected clinically.^[7] The primary tumor can be suspected and diagnosed from the morphology of the skin metastasis , using FNAC and histopathology.

This helps the clinician to start specific management of the patient at the earliest. It has been observed that many carcinomas spread through the lymphatic route to areas having common lymphatic drainage as that of the primary site.^[8] One study has evaluated the mechanisms responsible for the cutaneous metastasis and concludes that such mechanisms include factors other than chemokine receptors CCR10 and CXCR4, because their expressions by tumor cells are neither necessary nor sufficient for the formation of skin metastases.^[9] In women, breast carcinoma is the predominant malignancy, which metastasizes to the skin followed by lung, colorectal, renal and ovarian malignancies, while in men the most common tumor to metastasize to skin is carcinoma of the lung.^[2] It is extremely rare for gallbladder adenocarcinoma to present as cutaneous metastasis.^[3] Generally, gallbladder adenocarcinoma presents with non-specific symptoms of nausea, vomiting, anorexia, and weight loss and right upper quadrant pain. Primary carcinoma gallbladder spreads by direct extension and metastasis. The liver is most commonly affected organ by direct extension, with an incidence ranging from 60 to 90%, while regional lymph nodes are involved in about 60% of cases. Extra-abdominal metastasis is very rare and spreads by vascular dissemination and homing of tumor cells. The most common sites for metastases are the chest and abdomen, whereas other sites such as the extremities, neck, back, and scalp are rarely involved.^[10] The presence of cutaneous metastasis signifies a wide spread malignancy and is associated with grave prognosis.^[11]

CONCLUSION

Considering the high incidence of gall bladder cancer in India, possibility of gall bladder carcinoma metastases to skin should be kept in mind while searching for the primary. FNAC provides a quick and confident morphological diagnosis in these cases.

ACKNOWLEDGEMENT

Dr. Debasis Nandi Department of radiodiagnosis. B.S. medical college.

CONFLICT OF INTEREST

None.

REFERENCES

1. Nesseris I, Tsamakidis C, Gregoriou S, Ditsos I, Christofidou E, Rigopoulos D. Cutaneous metastasis of colon adenocarcinoma: case report and review of the literature. *Anais Brasileiros de Dermatologia*. 2013;88(6):56–8.
2. Nashan D, Müller ML, Braun-Falco M, Reichenberger S, Szeimies RM, Bruckner-Tuderman L. Cutaneous metastases of visceral tumours: a review. *J Cancer Res Clin Oncol*. 2009;135(1):1–14.

3. Mukhia R, Shrestha S, Malla K, Sharma VK. Cutaneous skin metastasis from Gallbladder Cancer. JNMA J Nepal Med Assoc. 2009;48(176):318–20.
4. Naser AMB, Zaki MS, Brunner M, Wollina V, Zouboulis CC. Cutaneous metastasis in internal malignancy. Egypt Dermatol Online J. 2007;3(1):4.
5. Marcoval J, Gallego MI, Moreno A. Inflammatory cutaneous metastasis as a first sign of recurrence of squamous cell carcinoma of the lung. Actas Dermosifiliogr. 2008;99(2):157–9.
6. Chopra R, Chhabra S, Samra SG, Thami GP, Punia RP, Mohan H. Cutaneous metastases of internal malignancies: A clinicopathologic study. Indian J Dermatol Venereol Leprol. 2010; 76(2):125–31.
7. Sariya D, Ruth K, Adams-McDonnell R, Cusack C, Xu X, Elenitsas R, *et al*. Clinicopathologic correlation of cutaneous metastases: experience from a cancer center. Arch Dermatol. 2007;143(5):613–20.
8. Bansal R, Naik R. A study of 70 cases of cutaneous metastases from internal carcinoma. J Indian Med Assoc. 1998;96(1):10–2.
9. Hu SC, Chen GS, Wu CS, Chai CY, Chen WT, Lan CC. Rates of cutaneous metastases from different internal malignancies: experience from a Taiwanese medical center. J Am Acad Dermatol. 2009;60(3):379–87.
10. C. H. E. Lai , W. Y. Lau. “Gallbladder cancer—a comprehensive review”. Surgeon. 2008; 6(2): 101–10.
11. Segura Huerta A, Pérez-Fidalgo JA, López Tendero P, Gironés Sarrió R. J. Aparicio Urtasun. An Med Interna. 2003;20(5): 251–3.

Cite this article: Mondal SK, Bhattacharjee D. FNAC diagnosis of gallbladder adenocarcinoma presenting as multiple skin nodules and jaundice. OGH Reports. 2017;6(1):23-5.